



Ten-step technique for navigated tubular transforaminal and extraforaminal lumbar interbody fusion

Ahmet Kartal^{1#^}, Minaam Farooq^{1#}, Mousa K. Hamad¹, Rachel Bratescu¹, Chibuikem A. Ikwuegbuenyi¹, Noah Willett¹, Blake I. Boadi¹, Jessica Berger¹, Alan Hernández-Hernández², Pedro Leonardo Villanueva-Solórzano², Roger Härtl¹

¹Department of Neurological Surgery, Och Spine at NewYork-Presbyterian Hospital, Weill Cornell Medicine, New York, NY, USA; ²National Institute of Neurology and Neurosurgery, Mexico City, Mexico

Contributions: (I) Conception and design: A Kartal, M Farooq, MK Hamad, R Härtl; (II) Administrative support: R Härtl; (III) Provision of study materials or patients: R Härtl; (IV) Collection and assembly of data: A Kartal, R Härtl; (V) Data analysis and interpretation: A Kartal, MK Hamad, N Willett, R Härtl; (VI) Manuscript writing: All authors; (VII) Final approval of manuscript: All authors.

[#]These authors contributed equally to this work.

Correspondence to: Roger Härtl, MD. Department of Neurological Surgery, Och Spine at NewYork-Presbyterian Hospital, Weill Cornell Medicine, 525 East 68th Street, Box 99, New York, NY 10065, USA. Email: roh9005@med.cornell.edu.

Abstract: Minimally invasive transforaminal lumbar interbody fusion (mTLIF) is an effective technique for treating degenerative lumbar spinal disorders that have failed nonoperative interventions and require fusion with or without decompression. mTLIF is technically challenging and requires significant experience with percutaneous instrumentation and microsurgical decompression techniques, which contributes to variability among surgeons and a challenging learning curve. Based on our extensive experience, we present a ten-step technique for performing mTLIF that integrates advanced technologies to enhance safety, efficiency, and reproducibility, and describe minimally invasive extraforaminal lumbar interbody fusion (mELIF), an intertransverse approach that serves as a valuable alternative—particularly in revision surgeries or cases with significant foraminal pathology—by minimizing dural exposure and reducing incidental tears. The objective is to present our experience and provide recommendations through detailed ten-step workflows for performing a total three-dimensional (3D) navigated tubular mTLIF and mELIF using expandable interbody cages and single-step navigated pedicle screws. We retrospectively reviewed our experience with mTLIF and mELIF procedures, based on a total of 350 cases, to develop step-by-step surgical techniques and workflows. These techniques were supplemented by illustrations and operative videos demonstrating the key steps. Our overview documents the key technical details for the reliable and reproducible performance of mTLIF and mELIF. Across 350 patients, complications occurred exclusively in the mTLIF cohort (2.1%), including cerebrospinal fluid (CSF) leak, wound infection, and hardware complications, with no neurological complications reported. Median hospital stay was shorter for mELIF (24 hours) compared to mTLIF (48 hours). Median follow-up time was 2.0 years. We present a comprehensive ten-step workflow for navigated mTLIF and mELIF. This workflow integrates three key features: (I) total 3D navigation, eliminating radiation exposure for the surgical team while minimizing radiation to the patient; (II) the use of expandable cages to enhance segmental lordosis; and (III) single-step navigated pedicle screws designed to streamline the surgical workflow. By providing clear and standardized workflows, we aim to support the education and training of surgeons, enabling consistent and safe outcomes.

Keywords: Minimally invasive spine surgery (MISS); minimally invasive transforaminal lumbar interbody fusion (mTLIF); minimally invasive extraforaminal lumbar interbody fusion (mELIF); navigation; surgical workflow

[^] ORCID: 0009-0007-4095-0798.

Submitted Jun 08, 2025. Accepted for publication Aug 08, 2025. Published online Dec 10, 2025.

doi: 10.21037/jss-25-89

View this article at: <https://dx.doi.org/10.21037/jss-25-89>

Introduction

Transforaminal lumbar interbody fusion (TLIF), introduced in 1982 (1) and progressively enhanced through unilateral laminotomy for bilateral decompression in 1997 (2,3), microendoscopic discectomy (MED) techniques (4), and the minimally invasive TLIF (mTLIF) approach in 2002 (5), is one of several lumbar interbody fusion (LIF) procedures alongside anterior (ALIF), lateral (LLIF), oblique (OLIF), and posterior (PLIF) methods (*Figure 1*).

Compared to open procedures, minimally invasive spine surgery (MISS) techniques, such as mTLIF, have

demonstrated lower perioperative complication rates compared to traditional open surgery (6), suggesting a favorable safety profile in appropriately selected patients. There is wide variability in how surgeons perform mTLIF procedures (7,8). Step-by-step workflows and metrics have been shown to be helpful for teaching and training surgeons (9). We have extensive previous experience in describing step-by-step workflows for a variety of minimally invasive spinal procedures. In 2017, we described the workflow for tubular decompression in lumbar disc herniation and lumbar spinal stenosis based on our previous clinical experience (10). We developed steps and metrics for the unilateral approach for bilateral decompression of lumbar stenosis (11) and subsequently demonstrated that adherence to these steps and metrics significantly improved surgeons' performance in spinal models (12). We then published step-by-step workflows for minimally invasive cervical tubular decompression (13) and spinal tumor resection (14). The senior author (R.H.) spearheaded the AOSpine MISS Task Force that developed an extensive set of educational materials for MISS procedures, including the mTLIF (11,15), which is available on the AO surgery reference app and is being used to teach and train spine surgeons. In this publication, we enhance the mTLIF workflows from the AO surgery reference app with advanced techniques and technologies, emphasizing minimally invasive extraforaminal lumbar interbody fusion (mELIF) as an effective revision strategy to minimize dural exposure and incidental tears, particularly in cases of prior laminectomy or foraminal pathology (16).

Our goal is to provide a comprehensive explanation of the sequential steps for mTLIF and mELIF, highlighting their indications, procedural details, and strategies for minimizing complications. We present this article in accordance with the SUPER reporting checklist (available at <https://jss.amegroups.com/article/view/10.21037/jss-25-89/rc>).

Methodology, surgical indications, and operative workflow

Methods

We analyzed patients who underwent tubular retractor-

Highlight box

Surgical highlights

- Two reproducible ten-step workflows for minimally invasive transforaminal lumbar interbody fusion (mTLIF) and minimally invasive extraforaminal lumbar interbody fusion (mELIF) using a microscope, tubular retractor, and total 3D navigation.
- mELIF uses an extraforaminal, intertransverse corridor that avoids canal entry and limits dural manipulation—ideal for revisions/foraminal stenosis.
- Outcomes (n=350): mELIF had shorter length of stay (24 vs. 48 h for mTLIF) and no revisions in a small cohort; mTLIF showed low complications (2.1%) and 7.1% revisions (mostly adjacent).

What is conventional and what is novel/modified?

- Transforaminal decompression with facetectomy (mTLIF), interbody fusion with cage, percutaneous pedicle screws, microscopic/tubular approach.
- “Total navigation” across all steps; single-step navigated pedicle screws (no K-wires); intertransverse mELIF with partial SAP undercutting and neuromonitoring; bullet/expandable cages to optimize lordosis (with cautious expansion); standardized, metric-driven ten-step workflow.

What is the implications, and what should change now?

- Adopt standardized, navigation-based ten-step workflows to improve accuracy/efficiency and eliminate staff radiation while minimizing patient dose.
- Select mELIF for unilateral foraminal pathology and scarred revisions without significant central stenosis; use caution at L5/S1.
- Use expandable cages judiciously, with meticulous endplate preparation, to minimize subsidence; prefer bullet-shaped cages for reliable midline placement.
- Incorporate step adherence metrics in training and reporting to enable consistency and benchmarking across centers.

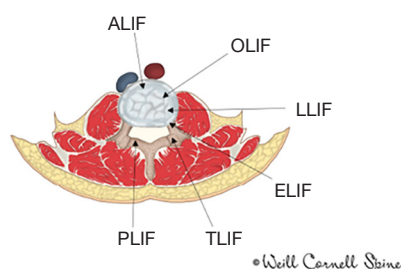


Figure 1 Different approaches to lumbar interbody fusion. ALIF, anterior lumbar interbody fusion; ELIF, extraforaminal lumbar interbody fusion; LLIF, lateral lumbar interbody fusion; OLIF, oblique lumbar interbody fusion; PLIF, posterior lumbar interbody fusion; TLIF, transforaminal lumbar interbody fusion.

assisted mTLIF (January 2015–July 2023) and mELIF (April 2023–October 2024) procedures performed by R.H. at Weill Cornell Medicine. Eligible patients were adults (aged 18 years or older) undergoing primary or revision procedures. Collected data included demographics, American Society of Anesthesiologists (ASA) scores, length of stay, operated levels, diagnoses, complications, revisions, and time-to-revision.

The study adhered to the Declaration of Helsinki and its subsequent amendments and was approved by the Weill Cornell Medicine Institutional Review Board (24-05027425). Informed consent for publication of images in the video guides was obtained from all participants and any identifiable individuals.

Indications for mTLIF

Degenerative disc disease, recurrent disc herniation, and mobile spondylolisthesis. Prolonged epidural scarring, arachnoiditis, ipsilateral conjoined nerve roots (which could obstruct access to the disc area), and osteoporosis are relative contraindications to this technique (17).

Indications for mELIF

In the absence of significant central spinal canal pathology, a unilateral extraforaminal technique can be used in complex revision cases with epidural adhesions to reduce the risk of dural tear. However, it does not directly address contralateral stenosis or radicular compression, relying instead on indirect decompression (18). L5/S1 pathologies may also present significant challenges, particularly with higher-grade spondylolisthesis.

Operative setup and image-guided workflow

LIFs involve the placement of an implant (cage, spacer, or structural graft) in the intervertebral space after discectomy and endplate preparation. The procedure is performed under general anesthesia with the patient in a prone position, using a microscope and navigation throughout the procedure [“Total Navigation” (19)] to ensure optimal visualization and precise localization. We perform intraoperative computed tomography (CT) scans using the AIRO scanner (Stryker, Portage, MI, USA), minimizing patient radiation exposure by restricting the scan area to the essential region and applying the lowest effective radiation dose. *Figure 2* illustrates the operating room set-up for the procedure. A complete list of standard surgical instruments is provided in [Appendix 1](#) and illustrated in *Figure 3*. We refer readers to our previously published ten-step paper on microsurgical techniques and the AO surgery reference app (10,15) for complementary details and procedural guidance relevant to the decompression techniques discussed in this manuscript.

Step-by-step descriptions

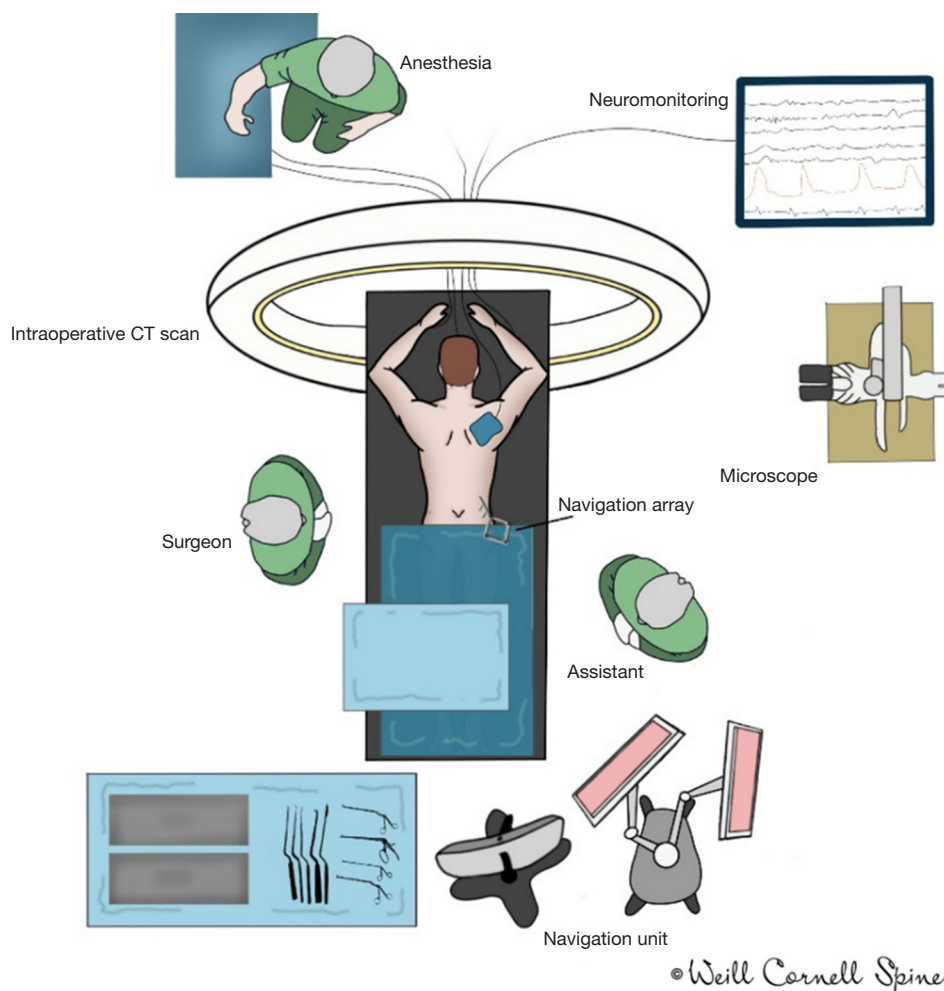
mTLIF

The surgical goal is direct nerve root and, when indicated, thecal sac decompression, interbody cage placement, and segmental stabilization with pedicle screws.

The surgeon stands on the facetectomy side with the assistant opposite. An intraoperative low-dose CT scan for navigation is performed after placing the reference array with a 2-pin fixation into the iliac crest. A navigated pointer confirms operative levels. Two small parallel skin incisions are made about 4–7 cm off midline in a perfect trajectory for pedicle screw placement, and screws are placed through a fascial incision as previously described using a single-step navigated pedicle screw system (20,21). The use of separate K-wires is not necessary, and most screws are placed in a single-step fashion. If the pedicle is very small or the bone is hard, we use a navigated 4.5–5.5 mm awl-tip tap (DePuy Synthes, Raynham, MA, USA) to tap the hole first, mark the screw using navigation software, and then place the actual navigated screw.

The surgical workflow proceeds in a reproducible step-by-step fashion from surgical landmark to landmark:

- (I) Ipsilateral inferior medial edge of lamina (IMEL);
- (II) Ipsilateral pars interarticularis (Pars);



© Weill Cornell Spine

Figure 2 Optimal operating room setup for mTLIF and mELIF surgeries. Patient is anesthetized and positioned in the prone position. The surgeon stands on the ipsilateral side of the pathology, while the assistant stands on the opposite side. The reference array for navigation is mounted on the contralateral iliac crest. Navigation unit and intraoperative CT or fluoroscopy is used for navigation. Nerve function is monitored using neuromonitoring. An operating microscope is used for a minimally invasive approach. CT, computed tomography; mELIF, minimally invasive extraforaminal lumbar interbody fusion; mTLIF, minimally invasive transforaminal lumbar interbody fusion.

- (III) Ipsilateral facet joint space (FJS);
- (IV) Caudal ipsilateral pedicle (caIP);
- (V) Cranial ipsilateral pedicle (crIP);
- (VI) Intervertebral disc space (Disc);
- (VII) Caudal contralateral pedicle (caCP).

For the placement of the tubular retractor, a medial fascial incision is made, and a blunt dilator is advanced to the *IMEL*. Under navigational guidance, the initial dilator is positioned over the lamina and medial facet joint. Sequentially larger dilators are then advanced with a twisting motion. Once navigation confirms correct tube

placement at the inferior laminal edge, the working channel is secured with a rigid holding arm and slightly angled medially. A 21-mm tubular retractor provides sufficient space for facet joint removal, decompression, and cage placement.

Under microscopic visualization, muscles overlying the bony structures are coagulated using the monopolar, and the facet capsule is opened. 3D navigation is used to identify or confirm all surgical landmarks. The *IMEL*, the *FJS*, and the ipsilateral *Pars* are visualized. The inferior articular process (IAP) is resected using a high-speed burr from *IMEL* to the *Pars* in an L-shaped or curved course. The

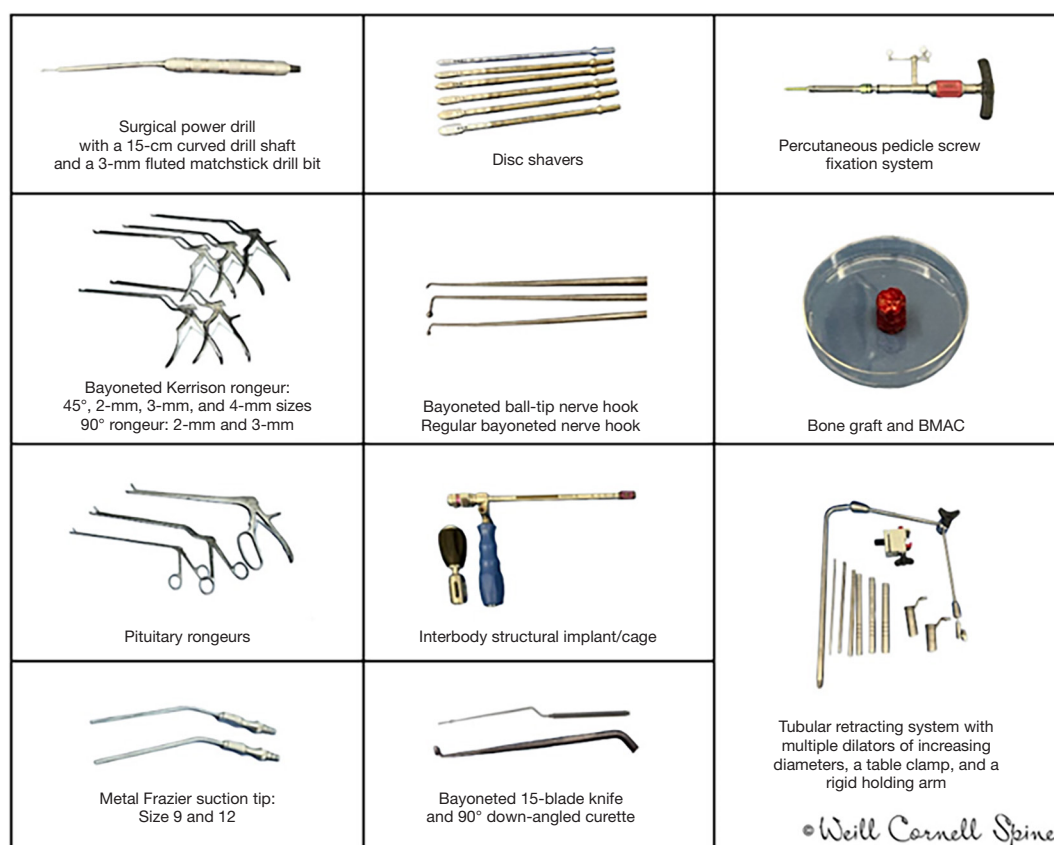


Figure 3 Standard surgical instruments. BMAC, bone marrow aspirate concentrate.

bone is harvested for fusion. This is followed by resection of the superior facet along the level of the superior border of the *caIP*, followed by resection of the ligamentum flavum from medial to lateral to expose the disc space. The *Disc* and exiting nerve root are then identified and visualized. The *crIP* is identified if a thorough decompression of the exiting nerve root is needed. A nerve root retractor is utilized to protect the lateral border of the thecal sac and traversing nerve root. The discectomy is followed by sequential distraction of the interbody space using shavers of increasing diameter, followed by meticulous endplate preparation for fusion using bayoneted 90-degree down-angled curettes (#0, #2, and #4/0).

Morselized autograft from the facet joint is inserted anteriorly into the intervertebral disc space and directed contralaterally to create space for the implant. Then, the structural implant is placed. We prefer using bullet-shaped cages instead of banana-shaped cages for navigational

purposes and optimal midline implant placement. When using bone morphogenetic protein (BMP), we apply the smallest effective dose—one sponge containing 1.05 mg of recombinant human bone morphogenetic protein-2 (rhBMP-2)—placing it as far anteriorly as possible, followed by the autograft bone. Cage expansion is performed with meticulous care to minimize the risk of subsidence, recognizing the associated learning curve (22). An “over-the-top” decompression (10) is performed if needed through ventral undercutting of the contralateral lamina and lateral recess. Identifying the *caCP* assists with orientation during this step and confirms adequate decompression. Rods and caps are placed and locked. An intraoperative CT scan is performed to confirm the accurate placement of the cage and screws.

Table 1 summarizes the mTLIF procedure in ten steps, illustrated in *Figure 4*. A step-by-step operative guide demonstrating this navigated tubular mTLIF workflow is

Table 1 Ten-step technique for mTLIF

1. Screw placement: bilateral navigated pedicle screw placement. Use 3D navigation for orientation and identification of landmarks throughout the procedure
2. Tube placement: under navigation, place the tube along the ipsilateral *IMEL* and opening of the *FJS* and *Pars*
3. Osteotomy IAP: resect the IAP using a high-speed burr from the *IMEL* to the *Pars* in an L-shaped course and harvest bone for fusion
4. Osteotomy SAP and ligamentum flavum resection: identify the *calP*. Resect the superior facet along the superior border of the *calP*, followed by resection of the ligamentum flavum from medial to lateral to expose the disc space
5. Nerve root decompression: the *crIP* is identified if a thorough decompression of the exiting nerve root is needed
6. Discectomy: mobilize the dura and visualize the *Disc* space. Perform a discectomy followed by distraction of the interbody space and preparation of the endplates. Use navigation to determine the trajectory for discectomy
7. Implant placement: place morselized bone graft in the anterior portion of the discectomy space. Under navigation, insert and gently expand the structural implant, and backfill with bone graft
8. Over-the-top decompression (if indicated): perform a contralateral over-the-top decompression guided by the *caCP* as a landmark
9. Final inspection and hemostasis: perform a clockwise inspection and ensure meticulous hemostasis. Carefully remove the tube under direct visualization
10. Rod placement and closure: bilateral rod placement followed by layered incision closure

caCP, caudal contralateral pedicle; calP, caudal ipsilateral pedicle; crIP, cranial ipsilateral pedicle; FJS, facet joint space; IAP, inferior articular process; IMEL, inferior medial edge of lamina; mTLIF, minimally invasive transforaminal lumbar interbody fusion; Pars, pars interarticularis; SAP, superior articular process.

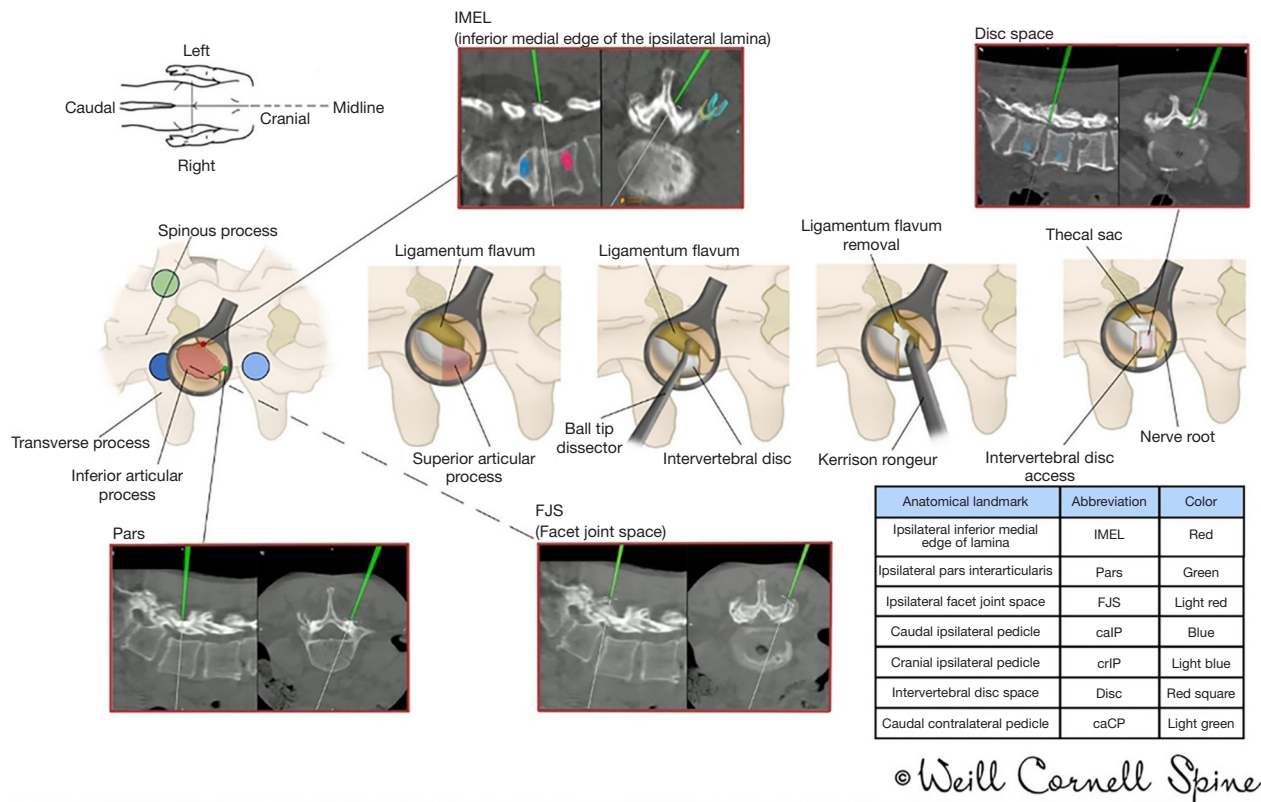
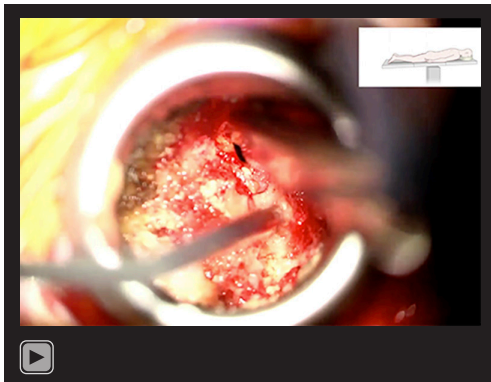


Figure 4 Anatomical landmarks for an mTLIF. mTLIF, minimally invasive transforaminal lumbar interbody fusion.



Video 1 Step-by-step video guide for mTLIF. mTLIF, minimally invasive transforaminal lumbar interbody fusion.

provided in *Video 1*.

mELIF

The surgical goal is to decompress the exiting nerve root via an intertransverse approach, typically indicated for unilateral foraminal stenosis with minimal central canal stenosis (18). This technique allows direct access to the posterolateral disc space, preserving muscle tissue and minimizing facet joint trauma. The preparation is similar to the mTLIF procedure. First, a low-dose intraoperative CT scan is obtained, with array placement contralateral to the interbody side. Incisions are precisely aligned with the optimal trajectory for pedicle screw placement. Navigated pedicle screw fixation is performed on the contralateral side as described above. On the ipsilateral side, the screw trajectory is tapped and marked on the navigation screen, but the screw is not placed. This will enable the placement of the tubular retractor at the docking point. For mELIF, it is not necessary to make a more medial fascial incision. Instead, the tubular retractor is placed through the same fascial incision as the screws.

The surgical workflow proceeds in a reproducible step-by-step fashion from surgical landmark to landmark:

- (I) Superior articular process (*SAP*);
- (II) Caudal transverse process (*caTP*);
- (III) Cranial transverse process (*crTP*);
- (IV) Ipsilateral *Pars*;
- (V) *Disc*.

A blunt dilator is passed through the incision until the intertransverse space is reached. The tube is placed over the superolateral edge of the *SAP*. Soft tissues are dissected

to expose and identify the *Pars*, the *crTP* and *caTP*, and the intertransverse ligament. The tube is tilted for exposure of the superior edge of the *caTP*, the *SAP* of the inferior vertebrae (medial), and the inferior edge of the *crTP*. The underlying disc can be palpated 5–10 mm deeper. After identifying the bony landmarks via navigation and palpation, crescent-shaped drilling extends from the upper border of the *caTP* to the lateral *SAP* and *Pars*. The key move to get under the intertransverse ligament is to then undercut the lateral *SAP* and *Pars* with Kerrison rongeurs. This will allow the medial insertion of the intertransverse ligament, located underneath the *SAP* and *Pars*, to be detached and retracted laterally with a ball-tip instrument, exposing the exiting nerve root and facilitating the approach to the *Disc*. Bleeding frequently occurs during the retraction of the intertransverse ligament; therefore, meticulous hemostasis is essential. This is all guided by navigation.

Disc removal and endplate preparation follow the mTLIF technique described above. While performing these steps, the exiting nerve root is visualized and protected if necessary. We routinely use intraoperative monitoring to stimulate the exiting nerve root before and after cage placement (23). The cage is placed with BMP due to the limited availability of autograft and is positioned with a medial trajectory, followed by ipsilateral pedicle screw insertion and a final CT scan.

Table 2 outlines the ten-step mELIF workflow depicted in *Figure 5* and is complemented by *Video 2*, which provides a navigated, step-by-step operative demonstration of the tubular mELIF technique. *Table 3* provides an overview of key technical distinctions between mTLIF and mELIF, while *Figures 6,7* illustrate the step-by-step cage placement for mTLIF and mELIF, respectively.

Closure

After meticulous hemostasis using bipolar cautery and hemostatic agents to minimize hematomas, pain, and muscle spasms, the tubular retractor is removed. The wound is then closed in a standard multilayer fashion (24), including fascial closure with interrupted sutures and intramuscular infiltration of clonidine and bupivacaine (Marcaine) for postoperative pain control (25).

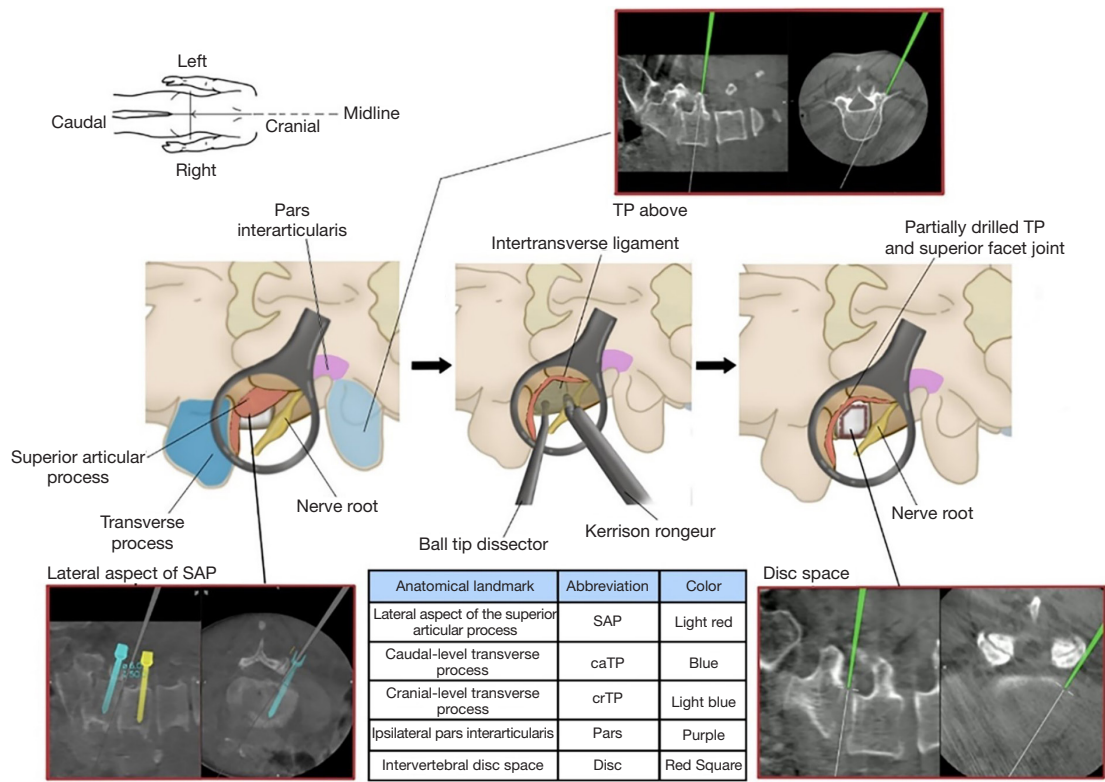
Postoperative considerations

Postoperative management emphasizes oral analgesia during the first postoperative week and early mobilization—

Table 2 Ten-step technique for mELIF

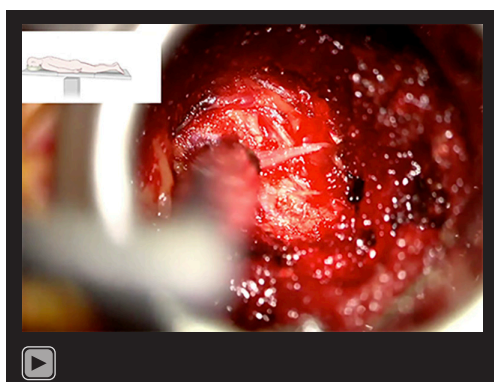
- 1. Screw placement: contralateral navigated screw placement and ipsilateral screw trajectory tapping and planning. Use 3D navigation for orientation and landmarks throughout the procedure
- 2. Tube placement: under navigation, place the tube over the lateral FJS and SAP. Removal of soft tissues and identification of the *Pars*, *crTP* and *caTP*, and the intertransverse ligament
- 3. Lateral facet drilling: crescent-like drilling of the upper portion of *caTP*, lateral *SAP*, and lateral *Pars*
- 4. Undercutting of *SAP/Pars*: undercut the lateral *SAP* and *Pars* using a Kerrison rongeur. Mobilize the intertransverse ligament, retract it laterally, and excise it.
- 5. Nerve root decompression: locate the exiting nerve root, perform stimulation if necessary, and decompress it.
- 6. Discectomy: visualize the *Disc* from its lateral aspect. Perform a discectomy guided by navigation, carefully protecting the exiting nerve root. Distract the *Disc* space and prepare endplates, using BMP and allograft bone due to the limited availability of autograft
- 7. Implant placement: cage placement under navigation. Backfill with bone graft.
- 8. Final inspection and hemostasis: perform a clockwise inspection and ensure meticulous hemostasis. Carefully remove the tube under direct visualization.
- 9. Screws/rod placement: perform ipsilateral screws and bilateral rod placement.
- 10. Closure: layered incision closure

BMP, bone morphogenetic protein; *caTP*, caudal transverse process; *crTP*, cranial transverse process; FJS, facet joint space; mELIF, minimally invasive extraforaminal lumbar interbody fusion; *Pars*, pars interarticularis; *SAP*, superior articular process.



© Weill Cornell Spine

Figure 5 Anatomical landmarks for an mELIF. mELIF, minimally invasive extraforaminal lumbar interbody fusion; SAP, superior articular process; TP, transverse process.



Video 2 Step-by-step video guide for mELIF. mELIF, minimally invasive extraforaminal lumbar interbody fusion.

initiated 3–4 hours after surgery—to reduce venous thromboembolism risk. When appropriate based on patient factors, procedures may be performed on an ambulatory basis; otherwise, most patients are discharged by postoperative day 1. Patients receive both verbal and written instructions to avoid lifting, bending, or twisting for at least 6 weeks. At 1–2 weeks postoperatively, patients undergo a surgical-site assessment and a focused neurologic examination, and most can resume work thereafter.

Tips and pearls

For transforaminal lumbar surgery, the target is Kambin's

Table 3 Comparison of mTLIF and mELIF

Category	mTLIF	mELIF
Indications	<ul style="list-style-type: none"> • Central stenosis • Foraminal, lateral recess stenosis • Up to grade II spondylolisthesis • All lumbar levels 	<ul style="list-style-type: none"> • Foraminal/extraforaminal stenosis • Up to grade I spondylolisthesis • All lumbar levels—L5/S1 can be difficult • Revision cases without central stenosis
Relative contraindications	<ul style="list-style-type: none"> • Significant epidural scarring • Ipsilateral conjoined nerve roots • Osteoporotic patients 	<ul style="list-style-type: none"> • Contralateral radicular compression • Central stenosis • L5/S1 can be difficult, especially with grade II spondylolisthesis
Incisions	<ul style="list-style-type: none"> • 2 skin, 3 fascial 	<ul style="list-style-type: none"> • 2 skin, 2 fascial
Screw placement	<ul style="list-style-type: none"> • Place all screws first 	<ul style="list-style-type: none"> • Contralateral screws placement, ipsilateral planning, drilling, and marking
Main bony surgical landmarks	<ul style="list-style-type: none"> • Ipsilateral IMEL • Ipsilateral Pars • Ipsilateral FJS • caIP • crIP • Intervertebral disc space (Disc) • caCP 	<ul style="list-style-type: none"> • SAP • caTP • crTP • Ipsilateral Pars • Disc space (Disc)
Tube docking points	<ul style="list-style-type: none"> • Medial facet—transition • Spinous process/lamina 	<ul style="list-style-type: none"> • Lateral facet
Bone graft	<ul style="list-style-type: none"> • Autograft +/- BMP/biomaterial 	<ul style="list-style-type: none"> • BMP/biomaterial

BMP, bone morphogenetic protein; caCP, caudal contralateral pedicle; caIP, caudal ipsilateral pedicle; caTP, caudal transverse process; crIP, cranial ipsilateral pedicle; crTP, cranial transverse process; FJS, facet joint space; IMEL, inferior medial edge of lamina; mELIF, minimally invasive extraforaminal lumbar interbody fusion; mTLIF, minimally invasive transforaminal lumbar interbody fusion; Pars, pars interarticularis; SAP, superior articular process.

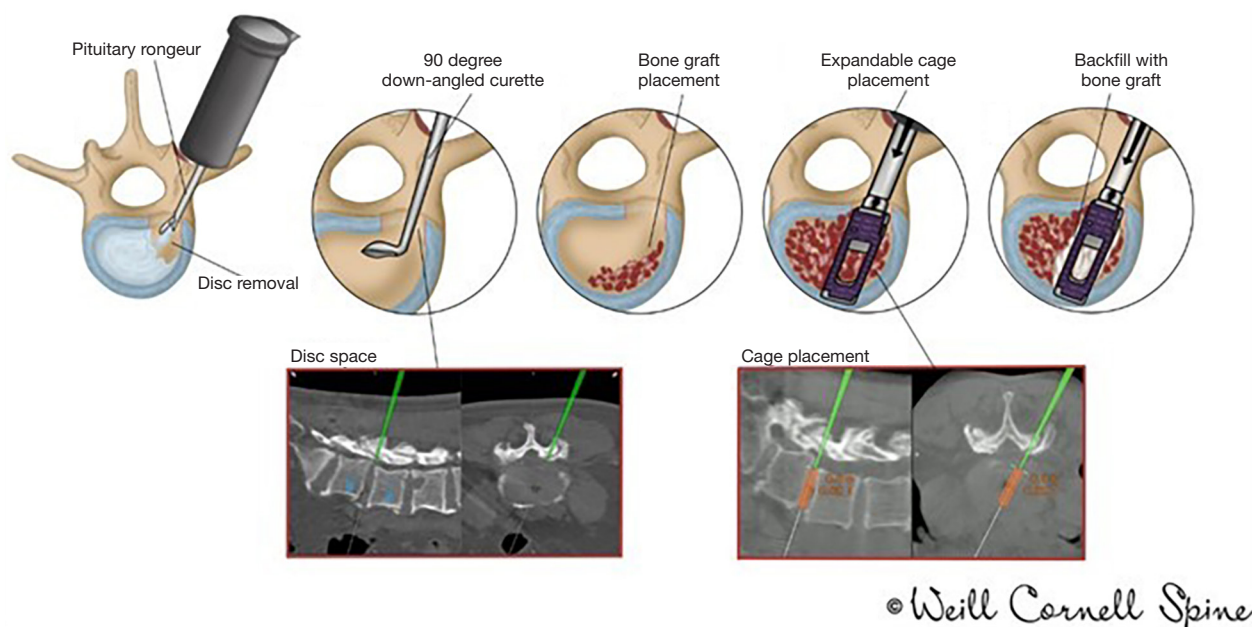


Figure 6 Step-by-step cage placement in mTLIF. mTLIF, minimally invasive transforaminal lumbar interbody fusion.

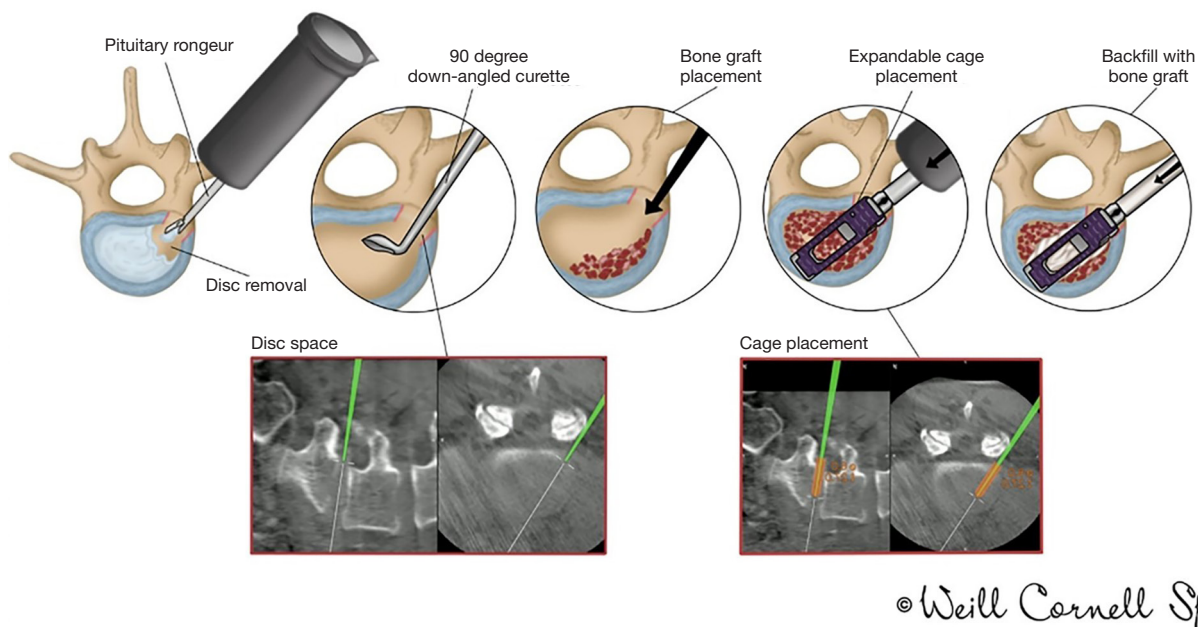


Figure 7 Step-by-step cage placement in mELIF. mELIF, minimally invasive extraforaminal lumbar interbody fusion.

triangle [or “Kambin’s prism” (26)], a triangle over the dorsolateral disc bordered by the exiting nerve root (hypotenuse), superior endplate of the inferior vertebra (base), and SAP (height). We favor the modified Kambin’s approach for mTLIF, with complete facetectomy for canal

decompression and nerve root visualization, using the dura and traversing nerve root as the vertical boundary. This modified Kambin’s triangle provides a “safe landing zone”, minimizing risk to the exiting and traversing nerve roots and facilitating visualization of foraminal abnormalities.

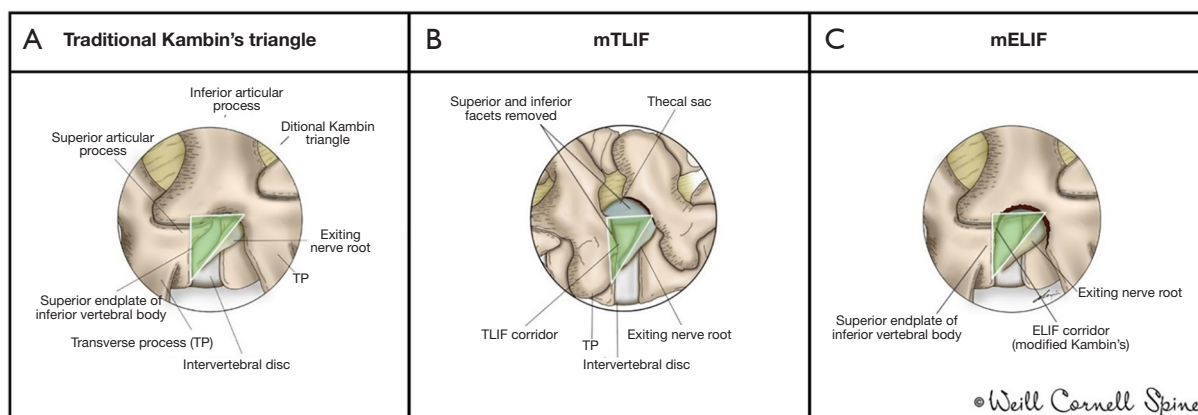


Figure 8 Kambin's triangle from the right side. The first view (A) shows the traditional Kambin's triangle, a surgical corridor bounded by the SAP, exiting nerve root, and vertebral body endplate (27), while the middle illustration (B) demonstrates the mTLIF corridor with removed facets, showing the thecal sac and exiting nerve root. The final view (C) depicts the mELIF corridor. ELIF, extraforaminal lumbar interbody fusion; mELIF, minimally invasive extraforaminal lumbar interbody fusion; mTLIF, minimally invasive transforaminal lumbar interbody fusion; SAP, superior articular process.

mELIF follows a more lateral path than traditional mTLIF, bypasses the IAP, and involves partial SAP resection, potentially minimizing nerve root manipulation. *Figure 8* illustrates various modifications of Kambin's triangle.

Compared to the mTLIF approach, the mELIF approach offers distinct technical advantages. It avoids direct canal exposure and manipulation of the thecal sac, significantly reducing the risk of dural tears, particularly in revision surgeries or cases with dense epidural scarring (18,28). Additionally, mELIF preserves posterior bony elements and musculature by requiring only partial resection of the superior articular process extraforaminally, resulting in less tissue disruption (29). Furthermore, it provides a direct lateral approach to decompress the exiting nerve root, making it especially advantageous for isolated foraminal stenosis or far-lateral disc herniations. However, mELIF is not recommended for cases with significant bilateral or central canal stenosis, where mTLIF remains preferable (18).

One variation of the mELIF is the endoscopic lumbar interbody fusion (EndoLIF). EndoLIF refers to a uniportal full-endoscopic lumbar interbody fusion, usually performed via a trans-Kambin (facet-sparing) or posterolateral TLIF (facet-sacrificing) approach (30,31), relying on visualization through a small endoscopic working channel. In contrast, mELIF employs a navigated tubular retractor under microscopic visualization after partial SAP resection, allowing direct decompression and better visualization of the exiting nerve. To protect the dorsal root ganglion,

we use minimal nerve retraction under direct view and continuous neuromonitoring during cage placement.

Navigation in spine surgery has demonstrated significant benefits over traditional fluoroscopy, including substantially reduced patient radiation doses (0.4 *vs.* 5.03 mSv) and greater screw accuracy (32-34). Radiation exposure remains crucial in MISS surgery, as minimally invasive techniques are associated with higher radiation exposure for the surgeon (35,36). Strategies to reduce exposure include limiting fluoroscopy time and dose, using protective gear appropriately, and handling equipment carefully (37). Advances from 2D imaging to intraoperative CT-based 3D navigation (iCT NAV) have significantly enhanced spinal navigation, expanding its applications beyond pedicle screws to interbody fusion, vertebral column resections, tumor resection, and complex spinal reconstructions. Our group introduced the concept of "total navigation", incorporating iCT NAV in all surgical steps—from skin incision and vertebral localization to implant verification and neural decompression (19). Total navigation has notably enhanced pedicle screw accuracy to 99%, reduced insertion time (average 3.1 minutes per screw), replaced fluoroscopy in 75% of spinal surgeries, of which the majority were MISS procedures, and eliminated radiation exposure to the staff completely (19). Similarly, our group reported a median accuracy rate of 95.2% for a 3D-navigated single-step pedicle screw system (SSPSS) placement across 135 screws, with a median insertion time of 2.45 minutes. This

Table 4 Demographic data, clinical, and procedure-related characteristics for patients undergoing an mTLIF and mELIF

Variable	Total mTLIF (n=340)	Total mELIF (n=10)
Age at surgery (years)	67.6 (59.4–73.7)	64.9±14.2
Gender (male)	191 (56.2)	5.0 (50.0)
BMI at surgery (kg/m ²)	26.9 (24.0–30.9)	26.2±3.7
ASA score		
I	3 (0.9)	0 (0.0)
II	155 (45.6)	6 (60.0)
III	89 (26.2)	4 (40.0)
IV	2 (0.6)	0 (0.0)
NA	91 (26.8)	0 (0.0)
Length of stay (hours)	48.0 (33.0–79.0)	24.0 (24.0–48.0)
Operated level		
L1–2	3 (0.8)	0 (0.0)
L2–3	10 (2.5)	0 (0.0)
L3–4	57 (14.6)	2 (18.2)
L4–5	215 (55.0)	9 (81.8)
L5–S1	106 (27.1)	0 (0.0)
Diagnosis	505	10
Spondylolisthesis	188 (37.2)	3 (30.0)
Spinal stenosis	202 (40.0)	6 (60.0)
Degenerative scoliosis	13 (2.6)	1 (10.0)
Others (ASD, DDD, HNP, tumor, synovial cyst)	102 (20.2)	0 (0.0)
Complications	7 (2.1)	0 (0.0)
CSF leak	1 (0.3)	0 (0.0)
Wound dehiscence and/or infection	2 (0.6)	0 (0.0)
Hematoma	0 (0.0)	0 (0.0)
Neurological deterioration	0 (0.0)	0 (0.0)
Hardware complications	4 (1.2)	0 (0.0)
Total number of patients with revision surgeries	24 (7.1)	0 (0.0)
Index level	4 (1.2)	0 (0.0)
Adjacent level	20 (5.9)	0 (0.0)
Time-to-revision (years)	2.0 (1.0–5.5)	

Continuous variables are presented as mean ± SD if normally distributed, or as median (IQR) if non-normally distributed. Categorical variables are presented as n (%). ASA, American Society of Anesthesiologists Physical Status classification; ASD, adjacent segment disease; BMI, body mass index; CSF, cerebrospinal fluid; DDD, degenerative disc disease; HNP, herniated nucleus pulposus; IQR, interquartile range; mELIF, minimally invasive extraforaminal lumbar interbody fusion; mTLIF, minimally invasive transforaminal lumbar interbody fusion; NA, not available; SD, standard deviation.

technique streamlines the procedure by eliminating the need for K-wires and traditional insertion steps, thereby reducing radiation exposure to operating room staff and enhancing overall surgical efficiency and safety (20,21).

One legitimate criticism of mTLIF is its limited ability to restore segmental lordosis, which can be partially overcome by using newer-generation expandable cages that expand both in height and lordosis. In an earlier study involving a subset of the 340 mTLIF patients, we observed a greater increase in segmental lordosis with expandable cages that expand in both height and lordosis compared to those that only expand in height ($4.4^{\circ}\pm 3.5^{\circ}$ vs. $2.1^{\circ}\pm 4.8^{\circ}$) (22). However, subsidence is a concern and requires careful endplate preparation and expansion. The surgeon's experience and learning curve significantly affect subsidence rates (22), highlighting the importance of cautious torque application during cage expansion in mTLIF surgery.

Discussion

We retrospectively analyzed the preoperative demographic data, clinical characteristics, and procedure-related details of 350 patients who underwent mTLIF (n=340) and mELIF (n=10) at our center between January 2015 and October 2024 (Table 4). Postoperative complications were observed only in the mTLIF group (2.1%), specifically cerebrospinal fluid leak (0.3%), wound dehiscence/infection (0.6%), and hardware complications (1.2%); notably, no neurological complications were observed. The median hospital stay was notably shorter for mELIF (24 hours) compared to mTLIF (48 hours). Median long-term follow-up was 2.0 years. Revision surgery was necessary exclusively in the mTLIF cohort (7.1%), predominantly at adjacent levels (5.9%) rather than at the index level (1.2%).

MISS techniques have gained prominence in recent years due to their significant advantages over traditional open approaches (38), including reduced disruption to the paraspinal muscle (39), minimal blood loss (40–43), shorter hospital length of stay (41,43,44), full return to daily activities (45), decreased complication rates (43,46), lowered surgery costs (43), and lower infection rates (47–49). Using our standardized workflow, mTLIF demonstrated a notably low revision rate of 7.1%, a median time-to-revision of 2 years, and a very low complication rate of 2.1%, aligning favorably with existing literature (50–53) and underscoring the efficacy and durability of our approach. These findings confirm that MISS provides excellent clinical outcomes, few complications, and a quick recovery.

We previously described a ten-step tubular decompression technique (10), complemented by an AO surgery reference guide for mTLIF (15) and the AOSpine MISS curriculum (15,54). We have also previously shown that step-by-step workflows facilitate the learning curve and improve surgical proficiency in surgical residents and fellows (12). Recently, we developed an augmented reality-guided workflow to further streamline the procedure for mTLIF (55). Building upon these established advantages, clearly defining what constitutes an mTLIF approach becomes essential for clinical consistency and effective patient counseling. Our group's previous systematic review (7) analyzed mTLIF literature to identify common defining features, including paramedian incisions, tubular retractors, microscopic or endoscopic visualization, and percutaneous screw-rod placement. Extensive subperiosteal dissection or wide exposure typically falls outside MISS criteria, highlighting the need for a standardized definition to improve research communication, accurate outcome reporting, and patient education.

Limitations

For mELIF procedures, our sample size was relatively small due to narrow selection criteria, which may not provide a comprehensive picture of mELIF outcomes. A larger cohort with a longer follow-up period would be necessary to draw more definitive conclusions about the efficacy and safety of mELIF compared to other techniques.

Conclusions

We outline a detailed, structured, and reproducible ten-step workflow for navigated mTLIF and mELIF, incorporating three key features: (I) total 3D navigation, eliminating radiation exposure for the surgical team while minimizing radiation to the patient; (II) the application of expandable cages to optimize segmental lordosis; and (III) single-step navigated pedicle screw placement intended to optimize the surgical workflow. We establish a foundation for enhancing surgical accuracy, safety, efficiency, and supporting surgeon education and training to achieve consistent operative outcomes. Further refinement of these workflows, supported by larger cohort studies and long-term outcome evaluations, will be essential for optimizing their clinical applications and advancing patient care in MISS.

Acknowledgments

None.

Footnote

Reporting Checklist: The authors have completed the SUPER reporting checklist. Available at <https://jss.amegroups.com/article/view/10.21037/jss-25-89/rc>

Peer Review File: Available at <https://jss.amegroups.com/article/view/10.21037/jss-25-89/prf>

Funding: None.

Conflicts of Interest: All authors have completed the ICMJE uniform disclosure form (available at <https://jss.amegroups.com/article/view/10.21037/jss-25-89/coif>). R.H. reports consulting relationships with DePuy Synthes, Brainlab, and Aclarion and serves as an advisor to RealSpine. He also has financial relationships with Realists and OnPoint outside the submitted work. The other authors have no conflicts of interest to declare.

Ethical Statement: The authors are accountable for all aspects of the work ensuring that questions related to the accuracy or integrity of any part of the work are appropriately investigated and resolved. The study was conducted in accordance with the Declaration of Helsinki and its subsequent amendments. This study was approved by the Weill Cornell Medicine Institutional Review Board (24-05027425). Informed consent was obtained from all participants and any identifiable individuals for the publication of this article and videos. A copy of the written consent is available for review by the editorial office of this journal.

Open Access Statement: This is an Open Access article distributed in accordance with the Creative Commons Attribution-NonCommercial-NoDerivs 4.0 International License (CC BY-NC-ND 4.0), which permits the non-commercial replication and distribution of the article with the strict proviso that no changes or edits are made and the original work is properly cited (including links to both the formal publication through the relevant DOI and the license). See: <https://creativecommons.org/licenses/by-nc-nd/4.0/>.

References

- Harms J, Rolinger H. A one-stager procedure in operative treatment of spondylolistheses: dorsal traction-reposition and anterior fusion (author's transl). *Z Orthop Ihre Grenzgeb* 1982;120:343-7.
- Spetzger U, Bertalanffy H, Naujokat C, et al. Unilateral laminotomy for bilateral decompression of lumbar spinal stenosis. Part I: Anatomical and surgical considerations. *Acta Neurochir (Wien)* 1997;139:392-6.
- Spetzger U, Bertalanffy H, Reinges MH, et al. Unilateral laminotomy for bilateral decompression of lumbar spinal stenosis. Part II: Clinical experiences. *Acta Neurochir (Wien)* 1997;139:397-403.
- Foley KT, Smith MM, Rampersaud YR. Microendoscopic approach to far-lateral lumbar disc herniation. *Neurosurg Focus* 1999;7:e5.
- Prabhu MC, Jacob KC, Patel MR, et al. History and Evolution of the Minimally Invasive Transforaminal Lumbar Interbody Fusion. *Neurospine* 2022;19:479-91.
- Bagan B, Patel N, Deutsch H, et al. Perioperative complications of minimally invasive surgery (MIS): comparison of MIS and open interbody fusion techniques. *Surg Technol Int* 2008;17:281-6.
- Lener S, Wipplinger C, Hernandez RN, et al. Defining the MIS-TLIF: A Systematic Review of Techniques and Technologies Used by Surgeons Worldwide. *Global Spine J* 2020;10:151S-67S.
- Tan SB, Foley K, Taboada N, et al. MIS-TLIF Comparison: Four Surgeons and Regions. In: Härtl R, Navarro-Ramirez R. editors. *Essential Step-by-Step Techniques for Minimally Invasive Spinal Surgery*. 1st ed. New York: Thieme; 2022.
- Sarmiento JM, Shahi P, Melissaridou D, et al. Step-by-step guide to robotic-guided minimally invasive transforaminal lumbar interbody fusion (MI-TLIF). *Ann Transl Med* 2023;11:221.
- Boukebir MA, Berlin CD, Navarro-Ramirez R, et al. Ten-Step Minimally Invasive Spine Lumbar Decompression and Dural Repair Through Tubular Retractors. *Oper Neurosurg* 2017;13:232-45.
- Melcher C, Korge A, Cunningham M, et al. Metrics Development for Minimal Invasive Unilateral Laminotomy for Bilateral Decompression of Lumbar Spinal Stenosis With and Without Spondylolisthesis by an International Expert Panel. *Global Spine J* 2020;10:168S-75S.
- Melcher C, Hussain I, Kirnaz S, et al. Use of a High-Fidelity Training Simulator for Minimally Invasive Lumbar Decompression Increases Working Knowledge and Technical Skills Among Orthopedic and Neurosurgical Trainees. *Global Spine J* 2023;13:2182-92.
- Hernandez RN, Wipplinger C, Navarro-Ramirez R, et al. Ten-Step Minimally Invasive Cervical Decompression via Unilateral Tubular Laminotomy: Technical Note and Early Clinical Experience. *Oper Neurosurg* 2020;18:284-94.
- McGrath LB Jr, Kirnaz S, Goldberg JL, et al. Microsurgical Tubular Resection of Intradural Extramedullary Spinal Tumors With 3-Dimensional-Navigated Localization. *Oper Neurosurg* 2022;23:e245-55.
- Massimo Balsano RH, Ibrahim Hussain. MISS Transforaminal lumbar interbody fusion (TLIF) for Lumbar spinal stenosis. Available online: <https://surgeryreference.aofoundation.org/spine/degenerative/lumbar/spinal-stenosis/miss-transforaminal-lumbar-interbody-fusion>
- Selznick LA, Shamji MF, Isaacs RE. Minimally invasive interbody fusion for revision lumbar surgery: technical feasibility and safety. *J Spinal Disord Tech* 2009;22:207-13.
- Mobbs RJ, Phan K, Malham G, et al. Lumbar interbody fusion: techniques, indications and comparison of interbody fusion options including PLIF, TLIF, MI-TLIF, OLIF/ATP, LLIF and ALIF. *J Spine Surg* 2015;1:2-18.
- Recoules-Arche D, Druschel C, Fayada P, et al. Unilateral Extraforaminal Lumbar Interbody Fusion (ELIF): Surgical Technique and Clinical Outcome in 107 Patients. *Clin Spine Surg* 2016;29:E162-70.
- Navarro-Ramirez R, Lang G, Lian X, et al. Total Navigation in Spine Surgery; A Concise Guide to Eliminate Fluoroscopy Using a Portable Intraoperative Computed Tomography 3-Dimensional Navigation System. *World Neurosurg* 2017;100:325-35.
- Bielecki M, Boadi BI, Xie Y, et al. High Accuracy of Three-Dimensional Navigated Kirschner-Wire-Less Single-Step Pedicle Screw System (SSPSS) in Lumbar Fusions: Comparison of Intraoperatively Planned versus Final Screw Position. *Brain Sci* 2024;14:873.
- Schmidt FA, Lekuya HM, Kirnaz S, et al. Novel MIS 3D NAV Single Step Pedicle Screw System (SSPSS): Workflow, Accuracy and Initial Clinical Experience. *Global Spine J* 2022;12:1098-108.
- Jitpakdee K, Sommer F, Gouveia E, et al. Expandable cages that expand both height and lordosis provide improved immediate effect on sagittal alignment and short-term clinical outcomes following minimally invasive transforaminal lumbar interbody fusion (MIS TLIF). *J*

- Spine Surg 2024;10:55-67.
23. Sommer F, Hussain I, Willett N, et al. Implementation and Feasibility of Mechanomyography in Minimally Invasive Spine Surgery. *J Pers Med* 2025;15:42.
 24. Alimi M, Njoku I Jr, Cong GT, et al. Minimally invasive foraminotomy through tubular retractors via a contralateral approach in patients with unilateral radiculopathy. *Neurosurgery* 2014;10 Suppl 3:436-47; discussion 446-7.
 25. Abdel Hay J, Kobaiter-Maarrawi S, Tabet P, et al. Bupivacaine Field Block With Clonidine for Postoperative Pain Control in Posterior Spine Approaches: A Randomized Double-Blind Trial. *Neurosurgery* 2018;82:790-8.
 26. Fanous AA, Tumialán LM, Wang MY. Kambin's triangle: definition and new classification schema. *J Neurosurg Spine* 2019;32:390-8.
 27. Tumialán LM, Madhavan K, Godzik J, et al. The History of and Controversy over Kambin's Triangle: A Historical Analysis of the Lumbar Transforaminal Corridor for Endoscopic and Surgical Approaches. *World Neurosurg* 2019;123:402-8.
 28. Kurzbuch AR, Recoules-Arche D. Minimal invasive lumbar spine revision surgery at distance from the dura and postsurgical scar tissue: Extraforaminal Lumbar Interbody Fusion (ELIF). *J Clin Neurosci* 2018;47:332-6.
 29. Eicker SO, Rhee S, Steiger HJ, et al. Transtubular microsurgical approach to treating extraforaminal lumbar disc herniations. *Neurosurg Focus* 2013;35:E1.
 30. Kim HS, Wu PH, Sairyo K, et al. A Narrative Review of Uniportal Endoscopic Lumbar Interbody Fusion: Comparison of Uniportal Facet-Preserving Trans-Kambin Endoscopic Fusion and Uniportal Facet-Sacrificing Posterolateral Transforaminal Lumbar Interbody Fusion. *Int J Spine Surg* 2021;15:S72-83.
 31. Hsu YC, Liu YF, Chang CJ, et al. Strategies to improve neurological safety in full-endoscopic lumbar fusion surgery: a comprehensive review. *Journal of Minimally Invasive Spine Surgery and Technique* 2024;9:S3-S13.
 32. Kraus MD, Krischak G, Keppler P, et al. Can computer-assisted surgery reduce the effective dose for spinal fusion and sacroiliac screw insertion? *Clin Orthop Relat Res* 2010;468:2419-29.
 33. Shin BJ, James AR, Njoku IU, et al. Pedicle screw navigation: a systematic review and meta-analysis of perforation risk for computer-navigated versus freehand insertion. *J Neurosurg Spine* 2012;17:113-22.
 34. Luther N, Iorgulescu JB, Geannette C, et al. Comparison of navigated versus non-navigated pedicle screw placement in 260 patients and 1434 screws: screw accuracy, screw size, and the complexity of surgery. *J Spinal Disord Tech* 2015;28:E298-303.
 35. Klingler JH, Sircar R, Scheiwe C, et al. Comparative Study of C-Arms for Intraoperative 3-dimensional Imaging and Navigation in Minimally Invasive Spine Surgery Part II: Radiation Exposure. *Clin Spine Surg* 2017;30:E669-76.
 36. Mendelsohn D, Strelzow J, Dea N, et al. Patient and surgeon radiation exposure during spinal instrumentation using intraoperative computed tomography-based navigation. *Spine J* 2016;16:343-54.
 37. Srinivasan D, Than KD, Wang AC, et al. Radiation safety and spine surgery: systematic review of exposure limits and methods to minimize radiation exposure. *World Neurosurg* 2014;82:1337-43.
 38. Alimi M, Hofstetter CP, Pyo SY, et al. Minimally invasive laminectomy for lumbar spinal stenosis in patients with and without preoperative spondylolisthesis: clinical outcome and reoperation rates. *J Neurosurg Spine* 2015;22:339-52.
 39. Bresnahan LE, Smith JS, Ogden AT, et al. Assessment of Paraspinal Muscle Cross-sectional Area After Lumbar Decompression: Minimally Invasive Versus Open Approaches. *Clin Spine Surg* 2017;30:E162-8.
 40. Patel AA, Zfass-Mendez M, Lebowhl NH, et al. Minimally Invasive Versus Open Lumbar Fusion: A Comparison of Blood Loss, Surgical Complications, and Hospital Course. *Iowa Orthop J* 2015;35:130-4.
 41. Miller LE, Bhattacharyya S, Pracyk J. Minimally Invasive Versus Open Transforaminal Lumbar Interbody Fusion for Single-Level Degenerative Disease: A Systematic Review and Meta-Analysis of Randomized Controlled Trials. *World Neurosurg* 2020;133:358-365.e4.
 42. Shakil H, Essa A, Malhotra AK, et al. Perioperative outcomes after minimally invasive and open surgery for treatment of spine metastases: a systematic review and meta-analysis. *J Neurosurg Spine* 2025;42:215-29.
 43. Pokorny G, Amaral R, Marcelino F, et al. Minimally invasive versus open surgery for degenerative lumbar pathologies: a systematic review and meta-analysis. *Eur Spine J* 2022;31:2502-26.
 44. Peng H, Tang G, Zhuang X, et al. Minimally invasive spine surgery decreases postoperative pain and inflammation for patients with lumbar spinal stenosis. *Exp Ther Med* 2019;18:3032-6.
 45. Shinn D, Mok JK, Vaishnav AS, et al. Recovery Kinetics After Commonly Performed Minimally Invasive Spine Surgery Procedures. *Spine (Phila Pa 1976)*

- 2022;47:1489-96.
46. Goldstein CL, Macwan K, Sundararajan K, et al. Perioperative outcomes and adverse events of minimally invasive versus open posterior lumbar fusion: meta-analysis and systematic review. *J Neurosurg Spine* 2016;24:416-27.
 47. Ee WW, Lau WL, Yeo W, et al. Does minimally invasive surgery have a lower risk of surgical site infections compared with open spinal surgery? *Clin Orthop Relat Res* 2014;472:1718-24.
 48. Mueller K, Zhao D, Johnson O, et al. The Difference in Surgical Site Infection Rates Between Open and Minimally Invasive Spine Surgery for Degenerative Lumbar Pathology: A Retrospective Single Center Experience of 1442 Cases. *Oper Neurosurg* 2019;16:750-5.
 49. Sweitzer SF, Sickbert-Bennett EE, Seidelman J, et al. The impact of minimally invasive surgical approaches on surgical-site infections. *Infect Control Hosp Epidemiol* 2024;45:557-61.
 50. Coban D, Changoor S, Saela S, et al. 224. Comparing 5-year outcomes between matched open and minimally invasive transforaminal lumbar interbody fusion in the treatment of single level lumbar degenerative disease. *The Spine Journal* 2022;22:S119.
 51. Wong AP, Smith ZA, Stadler JA 3rd, et al. Minimally invasive transforaminal lumbar interbody fusion (MI-TLIF): surgical technique, long-term 4-year prospective outcomes, and complications compared with an open TLIF cohort. *Neurosurg Clin N Am* 2014;25:279-304.
 52. Patel J, Kundnani V, Raut S, et al. Perioperative Complications of Minimally Invasive Transforaminal Lumbar Interbody Fusion (MI-TLIF): 10 Years of Experience With MI-TLIF. *Global Spine J* 2021;11:733-9.
 53. Kim CH, Easley K, Lee JS, et al. Comparison of Minimally Invasive Versus Open Transforaminal Interbody Lumbar Fusion. *Global Spine J* 2020;10:143S-50S.
 54. Schmidt FA, Wong T, Kirnaz S, et al. Development of a Curriculum for Minimally Invasive Spine Surgery (MISS). *Global Spine J* 2020;10:122S-5S.
 55. Sommer F, Hussain I, Kirnaz S, et al. Augmented Reality to Improve Surgical Workflow in Minimally Invasive Transforaminal Lumbar Interbody Fusion - A Feasibility Study With Case Series. *Neurospine* 2022;19:574-85.

Cite this article as: Kartal A, Farooq M, Hamad MK, Bratescu R, Ikwuegbuenyi CA, Willett N, Boadi BI, Berger J, Hernández-Hernández A, Villanueva-Solórzano PL, Härtl R. Ten-step technique for navigated tubular transforaminal and extraforaminal lumbar interbody fusion. *J Spine Surg* 2025;11(4):1013-1028. doi: 10.21037/jss-25-89